



Pacemakers as diagnostic tools

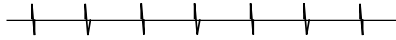
Tips for interpreting electrograms

Importance of e-grams

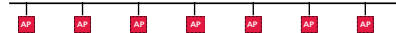


- Assess pacemaker function
- Diagnose arrhythmia
- Test pacemaker leads

Atrial e-gram

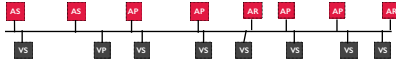


Atrial markers




What are you looking at?

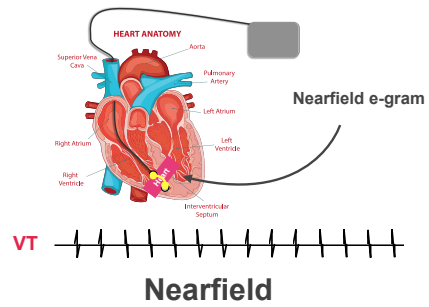
Markers



Know the markers



Beware single-channel e-grams



Nearfield

HEART ANATOMY

Superior Vena Cava, Aorta, Pulmonary Artery, Right Atrium, Right Ventricle, Interventricular Septum

Chamber catheter

Farfield e-gram

VT

Farfield

Atrial e-gram

Atrial markers

Use a ruler?

Takeaway message

Electrograms are very **different** from ECG's so slightly different **rules** apply.
